

# The Clinical Characteristics of *Anisakis* Allergy in Korea

Sung-Jin Choi<sup>1</sup>, Jae-Chun Lee<sup>2</sup>, Moo-Jung Kim<sup>1</sup>, Gyu-Young Hur<sup>1</sup>, Seung-Youp Shin<sup>3</sup> and Hae-Sim Park<sup>1</sup>

<sup>1</sup>Department of Allergy & Rheumatology, Ajou University School of Medicine, Suwon, Korea

<sup>2</sup>Department of Internal Medicine, Jeju National University, Jeju, Korea

<sup>3</sup>Department of Otolaryngology, Kyunghee University School of Medicine, Seoul, Korea

*Anisakidae* larvae can cause anisakiasis when ingested by humans. Although several groups have reported a gastrointestinal *Anisakis* allergy among people in Spain and Japan, our report is the first to summarize the clinical features of 10 *Anisakis* allergy cases in Korea. We enrolled 10 Korean patients (6 men and 4 women) who complained of aggravated allergic symptoms after ingesting raw fish or seafood. Sensitization to *Anisakis* was confirmed by detecting serum specific IgE to *Anisakis simplex*. The most common manifestation of anisakiasis was urticaria (100%), followed by abdominal pain (30%) and anaphylaxis (30%). All patients presenting with these symptoms also exhibited high serum specific IgE (0.45 to 100 kU/L) to *A. simplex*. Nine patients (90%) exhibited atopy and increased total serum IgE levels. The fish species suspected of carrying the *Anisakis* parasite were flatfish (40%), congers (40%), squid (30%), whelk (10%), and tuna (10%). *Anisakis simplex* should be considered as a possible causative food allergen in adult patients presenting with urticaria, angioedema, and anaphylaxis following the consumption of raw fish or seafood. (**Korean J Intern Med 2009;24:160-163**)

**Keywords:** *Anisakis simplex*; Fish; Food allergy

## INTRODUCTION

The development of food allergies is an increasingly common concern among consumers worldwide. In the United States, approximately 6% of infants and young children, and 3.7% of adults exhibit some degree of allergic reaction to certain foods. The most common causal foods in young children are cows' milk, eggs, peanuts, wheat, soy, tree nuts, fish, and shellfish; in adults, shellfish, peanuts, tree nuts, and fish lead the list [1].

*Anisakis simplex* is a nematode belonging to the order *Ascaridida*, family *Anisakidae*, and subfamily *Ascaridoidea*. Any fish or cephalopod species can be parasitized by third-stage *Anisakis* larvae. Codfish, hake, sardines, anchovies, salmon, tuna, and squid are among the most frequently parasitized species. The ingestion of third-stage *Anisakis*

larvae can cause anisakiasis in humans. Symptoms of anisakiasis arise when the nematode penetrates the gastric mucosa, which leads to serious abdominal and allergic symptoms [2].

Van Thiel et al. [3] reported the first case of anisakiasis, in the Netherlands in 1960. Subsequently, many cases have been reported in Japan and Western Europe, where raw fish are consumed frequently. Kim et al. [4] reported a case of *Anisakis* larvae present in the human oropharynx as the first case of anisakiasis in Korea, in 1971. Thereafter, several patients suffering acute anisakiasis and presenting mainly with gastrointestinal symptoms such as abdominal pain, nausea, vomiting, and diarrhea have been analyzed via gastroduodenoscopy.

Desowitz et al. [5] described a method for detecting specific IgE against *A. simplex* in 1985. Since that time,

**Received:** February 17, 2008

**Accepted:** July 16, 2008

### Correspondence to Hae-Sim Park, MD

Department of Allergy & Rheumatology, Ajou University School of Medicine, San-5 Wonchon-dong, Youngtong-gu, 443-721 Suwon, Korea  
Tel: 82-31-219-5196, Fax: 82-31-219-5154, E-mail: hspark@ajou.ac.kr

\* This study was supported by a grant from the Korean Health 21 R&D Project, Ministry of Health and Welfare, Republic of Korea (03-PJ10-PG13-GD01-0002).

**Table 1. Clinical features and laboratory findings of the 10 patients with *Anisakis* allergy**

Pt	Sex	Age (y)	Allergic symptoms	Fish Ingested	Atopy	Associated allergic disease	TEC (/mm <sup>2</sup> )	ECP (IU/mL)	Total IgE (IU/mL)	Specific IgE to <i>Anisakis</i> (kU/L)
1	M	22	URT, ANA	Conger	-	FA	100	58.7	453	92.4
2	F	52	URT	Flatfish, tuna	+	-	345	NC	302	2.29
3	M	52	URT, AP	Conger, flatfish	+	FA	300	NC	3,607	>100
4	F	57	URT, ANA	Squid	+	FA, AR, CU	100	200	296	8.72
5	M	45	URT, AP	Squid	+	-	0	NC	360	0.86
6	F	42	URT, AP	Flatfish	+	-	2,100	85.9	1,800	>100
7	M	70	URT	Squid	+	AR, CU	200	2.2	489	0.45
8	M	43	URT	Conger, flatfish	+	CU	120	18.5	475	1.11
9	M	47	URT	Conger	+	-	3,800	200	1,673	17.90
10	F	71	URT, ANA	Whelk	+	CU	30	NC	NC	1.49

Pt, patient; M, male; F, female; URT, urticaria; ANA, anaphylaxis; AP, abdominal pain; +, present; -, absent; FA, food allergy; AR, allergic rhinitis; CU, chronic urticaria; TEC, total eosinophil count; ECP, eosinophilic cationic protein; NC, not checked.

Kasuya et al. [6] have confirmed the allergic potential of *A. simplex* in two clinical reports and emphasized this species as a causative allergen related to fish consumption in urticaria patients. In Korea, since Kim et al. [7] reported the first case of gastroallergic anisakiasis, which developed after the patient had consumed raw fish on Jeju Island, there have been no published reports on *Anisakis*-induced allergic reactions, although Koreans freely ingest raw fish. Here, we report the clinical features of 10 Korean patients diagnosed with *Anisakis* allergies.

## CASE REPORT

Ten patients (6 men and 4 women) who developed abdominal pain, acute or chronic urticaria/angioedema, or anaphylaxis less than 24 hours after ingesting seafood were enrolled in our study. Sensitization to *A. simplex* was assessed by detecting serum specific IgE to *A. simplex* (ImmunoCAP System; Phadia, Uppsala, Sweden).

We investigated the clinical parameters of each patient, including age, gender, allergic symptoms, fish species ingested, associated allergic diseases including food allergies, atopic dermatitis, bronchial asthma, allergic rhinitis, chronic urticaria, and atopy status. Total eosinophil counts were measured in peripheral blood samples obtained from each patient. We also measured the serum total IgE, specific IgE to *A. simplex*, and eosinophilic cationic protein (ECP) level using an ImmunoCAP System (Phadia). Specific IgE to *Anisakis* was considered positive at >0.35 kU/L, according to the manufacturer's instruc-

tions. Atopy status was defined in patients showing a positive response to one or more common inhalant allergens such as house dust mites, tree pollen, and weed pollen on an allergic skin prick test.

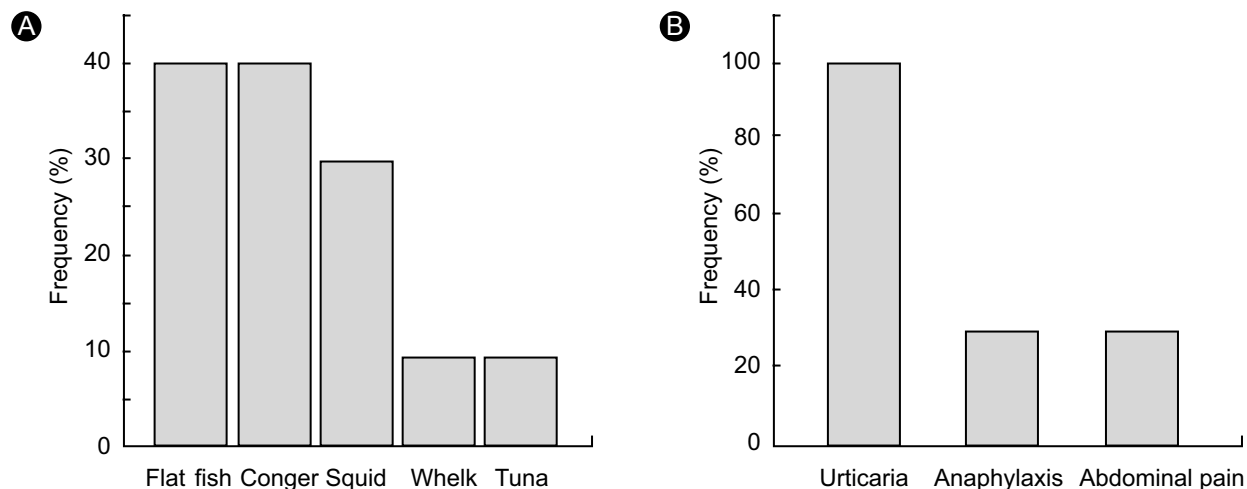
## Clinical features and laboratory findings

The clinical features and laboratory findings of the 10 patients with *Anisakis* allergy are summarized in Table 1. The mean age of the patients was 50 years (range, 22-71 years). All 10 patients had high serum specific IgE to *A. simplex*, ranging from 0.45-100 kU/L, and this was not related to the severity of the allergic reactions. Nine of the 10 patients (90%) had atopy. The levels of total serum IgE of these nine patients were increased. The total peripheral eosino-phil counts were above baseline in two patients, and all but one of the patients in whom the serum ECP level was assessed exhibited an increased ECP levels.

Chronic urticaria was noted in four patients (40%), food allergy was recorded in three (30%), and allergic rhinitis was exhibited by two (20%). Bronchial asthma and atopic dermatitis symptoms were not identified in any of the *Anisakis* allergy patients.

## Clinical symptoms and the implicated seafood source

The most common manifestation of anisakiasis in our study was urticaria/angioedema (100%), followed by abdominal pain (30%) and anaphylaxis (30%). The fish implicated in transmitting the parasites were flatfish (40%), congers (40%), squid (30%), whelk (10%), and



**Figure 1.** The fish species ingested (A) and the common allergic symptoms (B) in the patients with *Anisakis* allergies.

tuna (10%) (Fig. 1).

## DISCUSSION

Parasitic *A. simplex* can infest humans and cause anisakiasis when ingested with fish in its raw or undercooked form [2]. Since Kasuya et al. [6] first reported on *Anisakis* allergies in mackerel-induced urticaria patients in 1990, many *Anisakis*-induced allergic reactions have been reported, especially in Japan and Spain. Infestation with *A. simplex* causes direct tissue damage following an invasion of the gut wall, the development of an eosinophilic granuloma, the perforation of the gut, and strong allergic reactions [2]. The most frequent clinical manifestation of an *Anisakis* allergy is urticaria with or without facial angioedema [2]. Occasionally, anaphylactic shock occurs in patients exhibiting an *Anisakis* allergy.

Audicana et al. [8] reported the clinical manifestations of allergies attributable to *A. simplex* in 67 cases in Spain: urticaria/angioedema was observed in all patients, gastrointestinal symptoms occurred in 40% of the patients, and anaphylactic shock was observed in 12%. Overall, 88% of the patients expressed increased serum total IgE levels. Uncommon manifestations of anisakiasis include *Anisakis*-induced eosinophilic gastroenteritis, occupational disease, rheumatic manifestations, and contact dermatitis [9]. In our patient cases, we determined the most common allergic symptoms to be acute or chronic urticaria/angioedema, which was observed in all patients; abdominal pain and anaphylaxis occurred in

three (30%) patients. Most patients presented with atopy and high total serum IgE levels. This study represents the first report on the clinical features of 10 cases of *Anisakis* allergy in Korea. We suggest that *Anisakis* allergy should be considered in the differential diagnosis of Korean patients presenting with a range of allergic symptoms, from urticaria to anaphylactic shock, especially if these patients present with atopy and recent seafood ingestion.

*Anisakis simplex* is the most common hidden allergen in food [10]. Añíbarro et al. [10] described the role of hidden allergens in allergic reactions, reporting that of 530 allergic reactions to food, 119 (22.4%) cases were considered to be responses to hidden allergens. Furthermore, 65 reactions (12%) were anaphylaxis, and 38 (58.5%) of those were the result of hidden allergens. Añíbarro and colleagues [10] also showed that *A. simplex* was the cause of 58% of their anaphylaxis cases and was the most common cause of hidden food reactions (45%), followed by nuts (13%) and fish (7.9%). Thus, *A. simplex* should be considered a prevalent hidden allergen involved in food allergic reactions.

The fish species most frequently involved in *Anisakis* allergy are hake, anchovy, and cod, although studies have reported these fish in different orders of importance [2,9]. In our study, flatfish and congers were implicated most often, followed by squid, whelk, and tuna. These results differed from those of other studies [2]. We postulate that the differences result from variations in the fish species consumed in Korea. Flatfish and conger are the fish most frequently consumed raw in Korea; Seol et al. [11] stated that the main source of *Anisakis* infection in their patients

was *Conger myriaster*.

The diagnosis of *Anisakis* allergy is based on three criteria: a compatible history such as urticaria, angioedema, or anaphylaxis that developed following fish consumption; a positive skin prick test or the presence of serum specific IgE to *A. simplex*; and the lack of a reaction to proteins from the host fish [8,9]. In the present study, all of the patients had a history compatible with *Anisakis* allergy and had high serum specific IgE to *A. simplex*. All of the patients, with the exception of three who refused the test, showed negative responses to host fish extracts in skin prick tests. The failure to perform the skin test in three cases may be a limitation of our study.

The best treatment for anisakiasis is prophylaxis. The larvae cannot survive in temperatures above 60°C for 10 min or below -20°C for 24 h [9]. We requested that our patients avoid eating raw fish while we were monitoring allergic symptoms and serum specific IgE to *A. simplex*.

In conclusion, we recommend that *A. simplex* be considered as a possible causative food allergen in adults presenting with urticaria, angioedema, or anaphylaxis following raw fish or seafood consumption.

## REFERENCES

1. Sampson HA. Update on food allergy. *J Allergy Clin Immunol* 2004;113:805-819.
2. Moreno-Ancillo A, Caballero MT, Cabañas R, et al. Allergic reactions to *Anisakis simplex* parasitizing seafood. *Ann Allergy Asthma Immunol* 1997;79:246-250.
3. Van Thiel PH, Kuiper FK, Roskam RTH. A nematode parasitic to herring causing acute abdominal syndromes in man. *Trop Geogr Med* 1960;12:97-113.
4. Kim CH, Chung BS, Moon YI, Chun SH. A case report on human infection with *Anisakis* sp. in Korea. *Korean J Parasitol* 1971;9:39-43.
5. Desowitz RS, Raybourne RB, Ishikura H, Kliks MM. The radioallergosorbent test (RAST) for the serologic diagnosis of human anisakiasis. *Trans R Soc Trop Med Hyg* 1985;79:256-259.
6. Kasuya S, Hanano H, Izumi S. Mackerel-induced urticaria and *Anisakis*. *Lancet* 1990;335:665.
7. Kim SH, Kim HU, Lee JC. A case of gastroallergic anisakiasis. *Korean J Med* 2006;70:111-1166.
8. Audicana M, Garcia M, del Pozo MD, et al. Clinical manifestations of allergy to *Anisakis simplex*. *Allergy* 2000;55(S59):28-33.
9. Audicana MT, Ansotegui IJ, de Corres LF, Kennedy MW. *Anisakis simplex*: dangerous-dead and alive? *Trends Parasitol* 2002;18:20-25.
10. Añíbarro B, Seoane FJ, Múgica MV. Involvement of hidden allergens in food allergic reactions. *J Investig Allergol Clin Immunol* 2007;17:168-172.
11. Seol SY, Ok SC, Pyo JS, et al. Twenty cases of gastric anisakiasis caused by *Anisakis* type I larva. *Korean J Gastroenterol* 1994; 26:17-24.