

Cutaneous Metastases of Pancreatic Carcinoma as a First Clinical Manifestation

Dae Won Jun, M.D., Oh Young Lee, M.D., Chan Kum Park, M.D.²,
Ho Soon Choi, M.D., Byung Chul Yoon, M.D.,
Min Ho Lee, M.D. and Dong Hoo Lee, M.D.

Departments of Internal Medicine and Pathology², Hanyang University College of Medicine, Seoul, Korea

Cutaneous metastases from pancreatic adenocarcinomas are rare lesions. The most common site of cutaneous metastasis is the umbilicus, and this is also known as the 'Sister Mary Joseph' nodule. A 68-year-old Korean male, who was previously healthy and asymptomatic, was seen in the dermatology department for two subcutaneous nodules that he had on his right forearm and his back. Histological examination of the right forearm nodule revealed metastatic adenocarcinoma. Immunohistochemical staining for cytokeratin (CK) 7 and CK 19 were positive, and this strongly suggested the pancreatic duct as being the primary source of the cancer. The abdominal computed tomography findings were compatible with pancreatic cancer. Clinicians should be aware that metastatic cutaneous lesions could be the initial presenting sign for pancreatic cancer. The immunohistochemical staining for CK 7 and 19 may also be helpful in the diagnosis of metastatic pancreatic adenocarcinoma.

Key Words : Pancreatic cancer, Manifestation, Skin, Immunohistochemistry

INTRODUCTION

Cutaneous metastases occur in 0.7~0.9% of all patients with cancer, and the most frequent origins of cutaneous metastases are the breast, lung and colon cancer¹⁾. There are scant reports in the literature on the frequency of skin metastasis as the initial manifestation of a malignancy²⁻⁶⁾. The most frequent sites of metastasis for carcinoma of the pancreas are the lymph nodes, lung, liver, adrenal glands, kidney and bone⁷⁾. Cutaneous metastases are rare, and they are generally situated in the periumbilical area⁸⁾. To our knowledge, very few patients have been reported on with a solitary lesion or multiple cutaneous lesions that ultimately disclose a pancreatic adenocarcinoma. There was only one case report about pancreatic cancer skin metastasis in Korea, but the patient in that case complained of chest pain and dyspnea due to the malignant pleural effusion⁹⁾. We report here on a patient who presented with a metastatic skin lesion in an unusual location as the initial manifestation of

pancreatic cancer.

CASE REPORT

A 68-year-old Korean man was seen in the dermatology department because he had a painless subcutaneous right forearm nodule for 3 months. Two firm, 1.0 cm, subcutaneous nodules were noted on the physical examination (Figure 1). The histology revealed neoplastic gland cords or nests in the desmoplastic stroma, and this was consistent with metastatic adenocarcinoma (Figure 2). He was referred to the gastroenterology department to further investigate the source of the cutaneous lesion. He was totally asymptomatic except for the multiple subcutaneous nodules on his forearm, but he complained of a 5 kg weight loss during the last six months. His past medical history and family history were non-contributory. Apart from the subcutaneous nodules, the remainder of the

• Received : March 3, 2005

• Accepted : April 4, 2005

• Correspondence to : Oh Young Lee, M.D., Ph.D., Department of Internal Medicine, Hanyang University, 17 Haeng dang-dong, Sung dong-gu, Seoul, 133-792, Korea Tel : 82-2-2290-8343, Fax : 82-2-2290-8344, E-mail : leeoy@hanyang.ac.kr

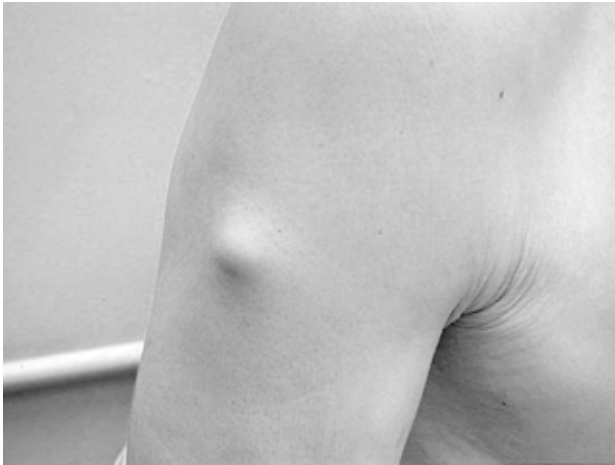

Figure 1. A firm subcutaneous nodule is noted on the right forearm.

exam was normal, including both the rectal and abdominal examinations that showed no masses. No enlarged lymph nodes were present, and the prostate was normal in size and consistency. The routine blood chemistry tests revealed only a slightly elevated alkaline phosphatase of 238 U/L (normal: 30~110 U/L), but there was a remarkable elevation in the tumor markers CA 19-9 to 486.9 U/mL (normal: 0.139 U/mL). The gastroscopy and colonoscopy exams revealed no specific abnormality except for a hyperplastic gastric polyp. The abdominal computed tomography (CT) detected a low-density mass located in the tail of the pancreas along with multiple liver metastases (Figure 3). The CT and ultrasonography findings of the abdomen were compatible with pancreatic cancer with multiple liver and cutaneous metastases. The immunohistochemical staining of the skin biopsy showed a positive reaction to monoclonal antibodies for CK 7, CK 19 and thyroid

transcription factor (TTF), and these markers are normally present in adenocarcinoma of the lung (Figure 4). The patient declined pancreatic fine needle aspiration biopsy and chemotherapy. Therefore, he was scheduled for follow-up.

DISCUSSION

We describe here an unusual case of pancreatic cancer presenting as subcutaneous nodules on the forearm and chest wall. Looking et al.⁶⁾ found that two out of 420 cases (0.47%) of cutaneous metastatic lesions had originated from pancreatic cancers. The most common site of cutaneous metastasis from the pancreas is the umbilicus, and this is known as 'Sister Mary Joseph's nodule'¹⁰⁾. Our case is unique in that the unusual cutaneous metastasis of pancreatic cancer as the first clinical manifestation was on the forearm and back, in contrast to the umbilicus. Also, the patient was asymptomatic from his pancreatic cancer on admission, and this was despite the neoplasm being located in the body and tail of the pancreas. Miyahara et al.¹¹⁾ reported on four cases in which cutaneous metastases presented prior to the diagnosis of pancreatic cancer. Cubilla et al.¹²⁾ reported that 8 of 50 cases (16%) of occult pancreatic cancer had metastatic skin lesions as the first manifestation of the malignancy. Our case and the other cases noted above reinforce the notion that metastatic skin lesions may be the first manifestation of an occult pancreatic malignancy. Takeuchi et al.¹³⁾ revealed that the tail of the pancreas was the most common site of the primary tumor, and the gross appearance of the cutaneous tumors in that study was oval, firm, solid, non-painful nodules. Although an excellent response to gemcitabine has been reported on in one case report¹⁴⁾, most of the patients died within 7 months.

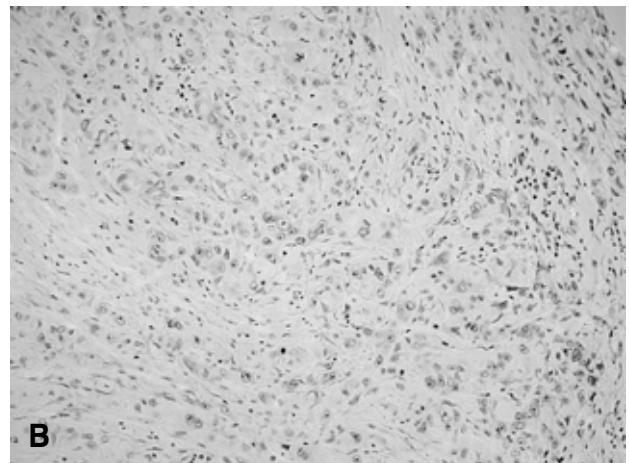
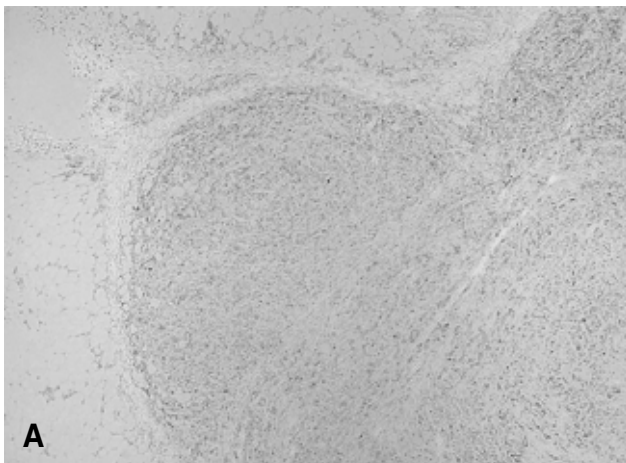


Figure 2. Light microscopic findings. (A) Excisional biopsy from forearm shows metastatic adenocarcinoma involving the subcutis (H&E stain, $\times 100$). (B) High power view shows well formed tubules and strands of adenocarcinoma cells with fibroplasia (H&E stain, $\times 200$)

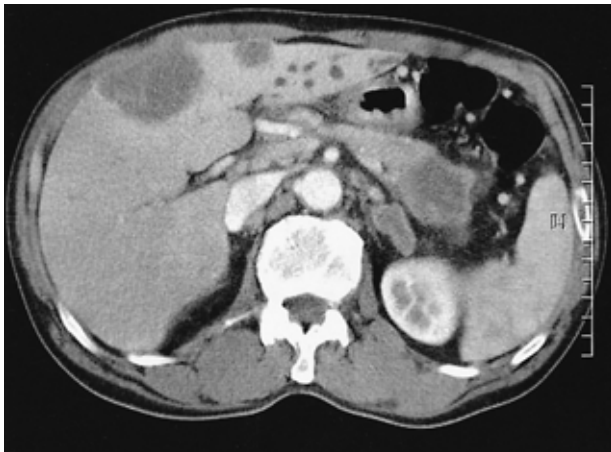

Figure 3. Abdomen computed tomography shows a low density mass in the tail of the pancreas along with multiple liver metastases.

Trying to determine the primary source of the cutaneous metastasis from occult tumor is very difficult. However, immunohistochemistry may enable the physician to precisely identify the primary neoplasm. CA 19-9, which was initially found in colorectal adenocarcinoma, has the highest sensitivity as a tumor marker for adenocarcinoma of the pancreas. This antigen is also found in other tumors, as well as in non-cancerous diseases. According to Ridwelski et al.¹⁵⁾, monoclonal antibodies against cytokeratin may be more specific and reliable than CA 19-9 at detecting disseminated tumor cells in lymph nodes. This is especially true because the false positivity or false negativity for CA 19-9 is related to the level of CA 19-9. Many different types of CK that are specific to various organs do exist. In the pancreas, CK 8 and CK 18 are produced by the exocrine acinar cells, the endocrine islets and the duct cells. CK 17 and CK 19 are usually found only in the ductal cells. Pancreaticobiliary ductal adenocarcinomas, in

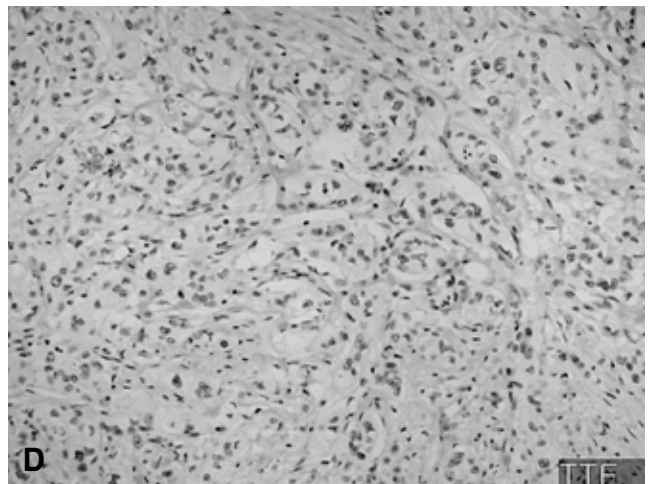
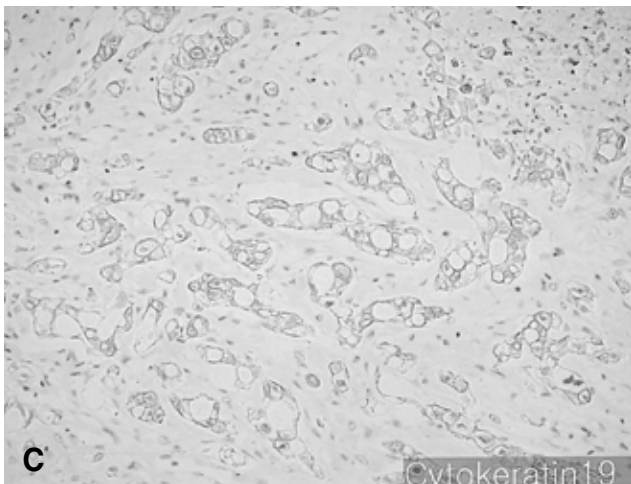
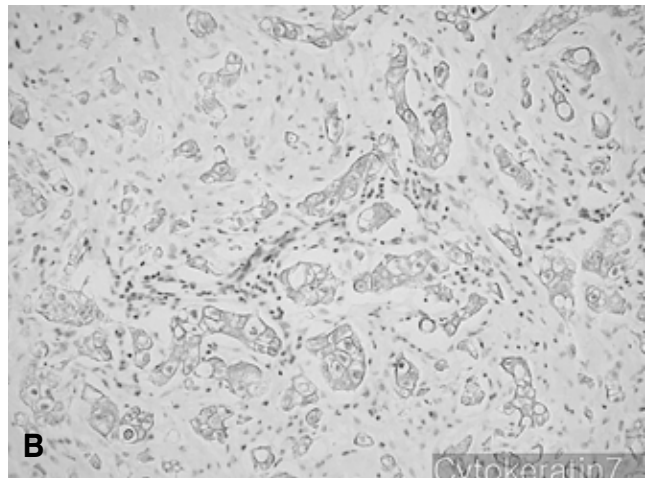
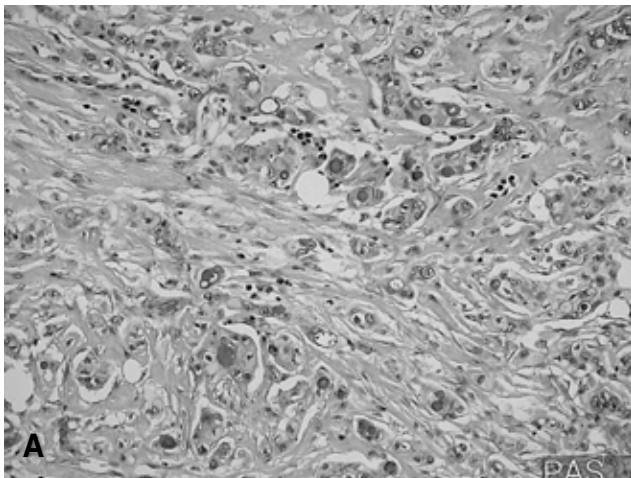


Figure 4. (A) There are PAS positive droplets in the lumen of neoplastic glands (PAS stain $\times 400$). (B, C) The neoplastic glands are positive for CK 7 and CK 19 immunostaining ($\times 400$). (D) The tumor cells were negative for TTF immunostaining ($\times 400$).

general, have a cytokeratin immunophenotype identical to that of normal pancreatic ducts, including being positive for CK 7, 8, 18 and 19¹⁶. Approximately 90% of pancreaticobiliary adenocarcinomas stain diffusely with CK 7 antibody and 50% stain diffusely with CK 19 antibody¹⁷. Duval et al¹⁸ have recently reported that the majority of pancreatic carcinomas and extrahepatic carcinomas were positive for CK 7 and negative for CK 20. Therefore, the findings concerning the immunohistochemical expression of CKs are considered as being useful in the diagnosis of metastatic carcinomas.

CONCLUSION

Cutaneous metastasis from pancreatic carcinoma is a rare finding. Clinicians should be aware that metastatic cutaneous lesions could be the initial presenting sign for pancreatic cancer. Also, the immunohistochemical staining for CK 7 and 19 may be helpful for the diagnosis of metastatic pancreatic adenocarcinoma.

REFERENCES

- 1) Schwartz RA. *Cutaneous metastatic disease*. *J Am Acad Dermatol* 33:161-182, 1995
- 2) Brownstein MH, Helwig EB. *Spread of tumors to the skin*. *Arch Dermatol* 107:80-86, 1973
- 3) Lookingbill DP, Spangler N, Sexton FM. *Skin involvement as the presenting sign of internal carcinoma*. *J Am Acad Dermatol* 22:19-26, 1990
- 4) Kanitakis J. *Les mtastases cutanes des cancers profonds*. *Presse Med* 22:631-636, 1993
- 5) Brownstein MH, Helwig EB. *Patterns of cutaneous metastasis*. *Arch Dermatol* 105:862-868, 1972
- 6) Lookingbill DP, Spangler N, Helm KF. *Cutaneous metastases in patients with metastatic carcinoma: a retrospective study of 4020 patients*. *J Am Acad Dermatol* 29:228-236, 1993
- 7) Tharakaram S. *Metastases to the skin*. *Int J Dermatol* 27:240-242, 1988
- 8) Ruiz de Erenchun Lasa F, Vazquez Doval FJ, Sola Casaa MA. *Metstasis cutneas de adenocarcinoma de pncreas*. *Actas Dermosifiliogr* 82:455-458, 1991
- 9) Kim HS, Lee SP, Park SU, Leu ST, O US, Lee JH, Kim HJ. *A case of the pancreatic carcinoma detected by cutaneous metastasis manifested as multiple nodules on whole body*. *Korean J Med* 66:432-436, 2004
- 10) Powell FC, Cooper AJ, Massa MC, Goellner JR, Su WP. *Sister Mary Joseph's nodule: a clinical and histologic study*. *J Am Acad Dermatol* 10:610-615, 1984
- 11) Miyahara M, Hamaoka Y, Kawabata A, Sato Y, Tanaka A, Yamamoto A, Ueno T, Nishihara K, Suzuki T. *Cutaneous metastases from pancreatic cancer*. *Int J Pancreatol* 20:127-130, 1996
- 12) Cubilla A, Fitzgerald PJ. *Pancreas cancer: I. duct adenocarcinoma, a clinical-pathologic study of 380 patients*. *Pathol Annu* 13:241-289, 1978
- 13) Takeuchi H, Kawano T, Toda T, Minamisono Y, Nagasaki S, Yao T, Sugimachi T. *Cutaneous metastasis from pancreatic adenocarcinoma: a case report and a review of the literature*. *Hepatogastroenterology* 50:275-277, 2003
- 14) Florez A, Roson E, Sanchez-Aguilar D, Peterio C, Toribio J. *Solitary cutaneous metastasis on the buttock: a disclosing sign of pancreatic adenocarcinoma*. *Clin Exp Dermatol* 25:201-203, 2000
- 15) Ridwelski K, Meyer F, Fahlke J, Kasper U, Roesner A, Lippert H. *Value of cytokeratin and Ca 19-9 antigen in immunohistological detection of disseminated tumor cells in lymph nodes in pancreas carcinoma*. *Chirurg* 72:920-926, 2001
- 16) Ohshio G, Imamura T, Okada N, Yamaki K, Suwa H, Imamura M, Sakahara H. *Cytokeratin 19 fragment in serum and tissues of patients with pancreatic diseases*. *Int J Pancreatol* 21:235-241, 1997
- 17) Baars JH, Ruijter JL, Smedts F, van Niekerk CC, Poels LG, Seldenrijk CA, Ramaekers FC. *The applicability of a keratin 7 monoclonal antibody in routinely Papanicolaou-stained cytologic specimens for the differential diagnosis of carcinoma*. *Am J Clin Pathol* 101:257-261, 1994
- 18) Duval JY, Savas L, Banner BF. *Expression of cytokeratins 7 and 20 in carcinomas of the extrahepatic biliary tract, pancreas, and gallbladder*. *Arch Pathol Lab Med* 124:1196-1200, 2000