IMAGES OF INTEREST

Korean J Intern Med 2026;41:1155-1157
https://doi.org/10.3904/kjim.2026.080

# Femoral sheath fracture and migration during temporary pacemaker removal: Successful bail-out using a balloon retrieval technique

Daeung Ohn, Yeon-Jik Choi, Junghoon Lee, and Suk-Min Seo

Division of Cardiology, Department of Internal Medicine, Eunpyeong St. Mary's Hospital, College of Medicine, The Catholic University of Korea, Seoul, Korea

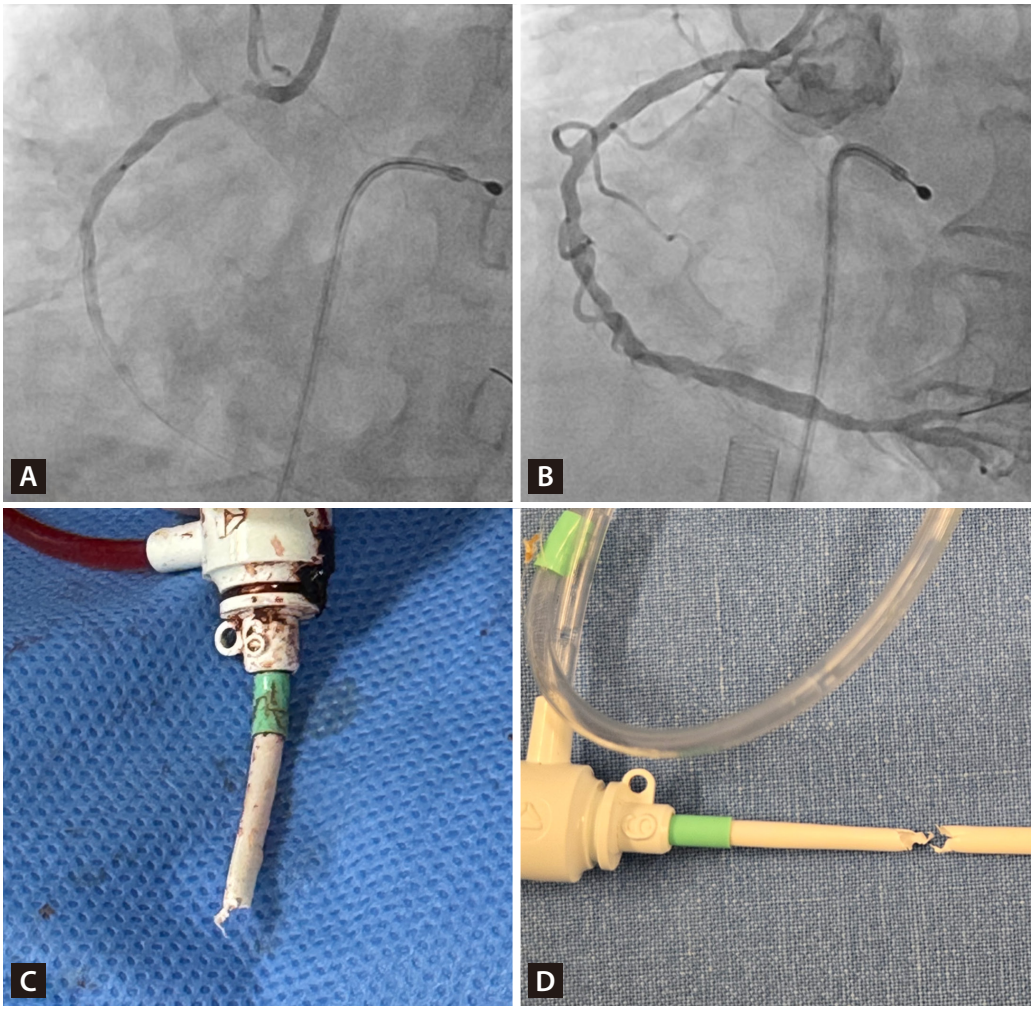


**Figure 1.** Coronary angiography and gross images of fractured sheath. (A) Coronary angiography showing a culprit lesion in the proximal right coronary artery. Because of complete atrioventricular block and severe bradycardia, a temporary pacemaker was inserted first. (B) Veno-arterial extracorporeal membrane oxygenation was applied, followed by successful stent implantation without catastrophic events. (C) Intraoperative image showing the proximal portion of the fractured sheath. (D) Entire sheath with a visible fracture line along the shaft, confirming complete disruption.

Copyright © 2026 The Korean Association of Internal Medicine
This is an Open Access article distributed under the terms of the Creative Commons Attribution Non-Commercial License (http://creativecommons.org/licenses/by-nc/4.0/) which permits unrestricted noncommercial use, distribution, and reproduction in any medium, provided the original work is properly cited.

pISSN 1226-3303
eISSN 2005-6648
http://www.kjim.org

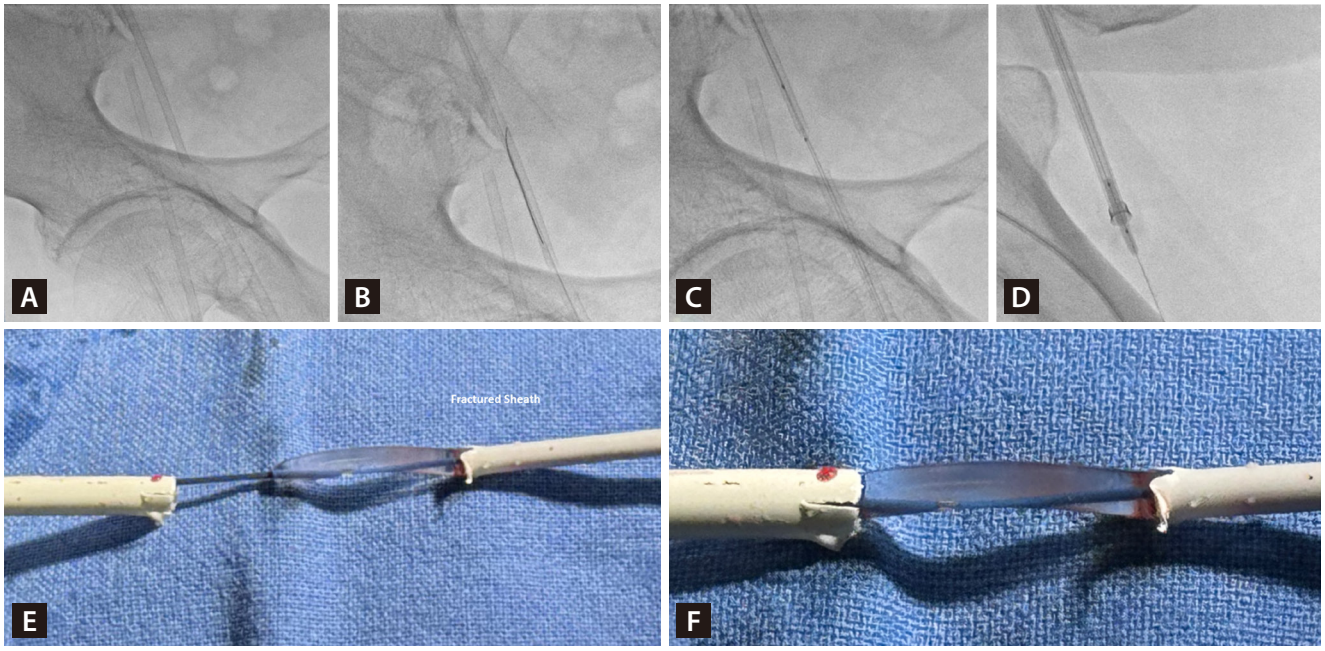


**Figure 2.** Fluoroscopic images and intraoperative images of balloon retrieval of fractured sheath. The right common femoral artery sheath was left in place throughout the procedure. (A) Repeat puncture of the right superficial femoral vein distal to the previous lock sheath site, followed by insertion of a 9 French sheath. (B) Advancement of a 0.014″ guidewire into the true lumen of the remnant sheath. (C) Placement of a 2.5 × 15 mm non-compliant balloon into the true lumen over the wire. (D) Balloon inflation and successful retrieval of the remnant sheath through the distal 9 French sheath. (E) Balloon inflated within the lumen of the fractured sheath remnant, securing the fragment. (F) The fractured sheath being drawn into the 9 French sheath by balloon traction, enabling successful retrieval.

A 93-year-old female presented with syncope and was diagnosed with an inferior wall ST-segment elevation myocardial infarction complicated by shock and complete atrioventricular block. Emergent temporary pacemaker (TPM) insertion, veno-arterial extracorporeal membrane oxygenation, and percutaneous coronary intervention (PCI) were performed.

The patient recovered uneventfully, and several days later underwent additional PCI for a non-culprit left main lesion. During removal of the right ventricular TPM, sheath fracture with migration occurred (Fig. 1). The patient was markedly obese (body mass index 37.8 kg/m²), and the relatively vertical course of the sheath in the right common femoral vein likely predisposed it to kinking and fracture.

Fortunately, fluoroscopy showed that the fractured sheath had not migrated far, remaining close to the adjacent femoral artery sheath. For bail-out, a repeat puncture was performed distal to the original sheath site and a 9 French sheath was inserted. A 0.014″ guidewire was advanced, followed by positioning of a 2.5 mm balloon within the lumen of the floating remnant. Inflation of the balloon allowed successful retrieval of the fragment into the 9 French sheath. To facilitate secure capture and retrieval of the irregularly torn sheath remnant, the distal end of the 9-French sheath was partially cut with scissors to widen and modify the tip (Fig. 2).

Foreign bodies within the venous system, if lodged in the pulmonary artery, right atrium, or right ventricle, may rarely cause ventricular arrhythmia or thrombus formation; thus, removal is mandatory [1-3]. The most common etiology is catheter fracture, usually managed by snaring, with percutaneous retrieval success rates nearly 100% [1-3]. In this case, although snare technique was possible, the relatively large 6 French sheath fragment prompted the use of balloon traction to minimize vascular injury.

Informed consent was obtained from patients.

## REFERENCES

1. Cheng CC, Tsai TN, Yang CC, Han CL. Percutaneous retrieval of dislodged totally implantable central venous access system in 92 cases: experience in a single hospital. Eur J Radiol 2009;69:346-350.
2. Leite TFO, Pazinato LV, Bortolini E, Pereira OI, Nomura CH, Filho JMDML. Endovascular removal of intravascular foreign


https://doi.org/10.3904/kjim.2026.080

bodies: a single-center experience and literature review. Ann Vasc Surg 2022;82:362-376.
3. Woodhouse JB, Uberoi R. Techniques for intravascular foreign body retrieval. Cardiovasc Intervent Radiol 2013;36:888-897.

**Received** : February 13, 2026
**Accepted** : April 24, 2026

**Correspondence to**
Suk-Min Seo, M.D., Ph.D.
Division of Cardiology, Department of Internal Medicine, Eunpyeong St. Mary's Hospital
College of Medicine, The Catholic University of Korea, 1021 Tongil-ro, Eunpyeong-gu, Seoul 03312, Korea
Tel: +82-2-2030-2956, Fax: +82-2-2030-4641
E-mail: ssm530@catholic.ac.kr
https://orcid.org/0000-0003-2424-5275

**CRedit authorship contributions**
Daeung Ohn: conceptualization, investigation, writing - original draft, writing - review & editing, visualization; Yeon-Jik Choi: writing - review & editing, project administration; Junghoon Lee: writing - review & editing, supervision; Suk-Min Seo: writing - original draft, writing - review & editing, supervision, project administration

**Conflicts of interest**
The authors disclose no conflicts.

**Funding**
None