IMAGES OF INTEREST

Korean J Intern Med 2026;41:1158-1159
https://doi.org/10.3904/kjim.2026.237

Isolated right ventricular infarction during percutaneous coronary intervention

Chan-Hee Lee[1], Young-Sang Jeong[1], and Melvin M. Scheinman[2]

[1]Division of Cardiology, Department of Internal Medicine, Yeungnam University Medical Center, Daegu, Korea; [2]Division of Cardiology, Section of Electrophysiology, University of California San Francisco, San Francisco, CA, USA

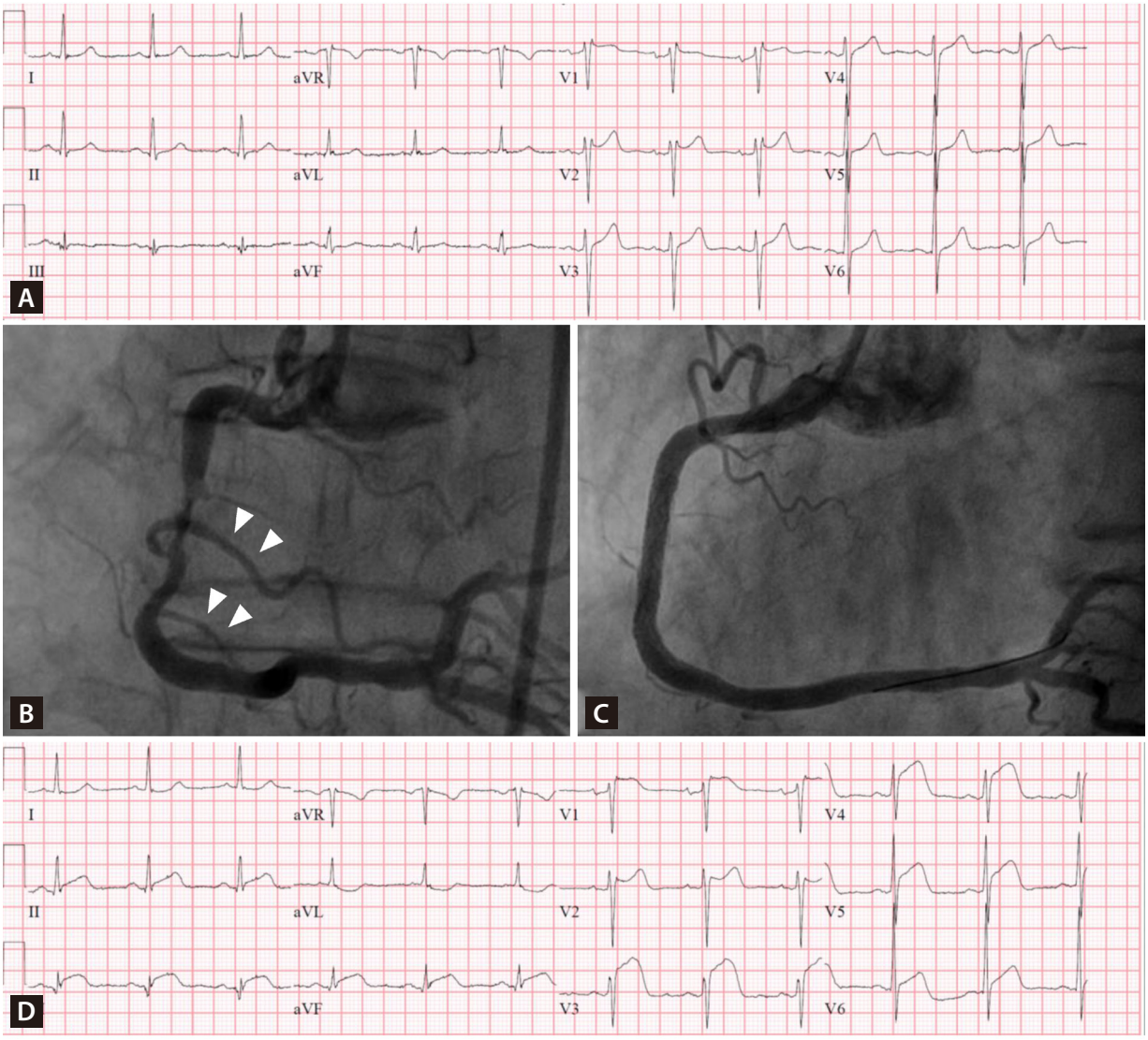

Figure 1. Electrocardiogram and Right coronary angiogram findings. (A) Initial electrocardiogram (ECG). (B) Coronary angiography revealed an irregular stenosis of up to 80% in the middle portion of the right coronary artery (RCA). The right ventricular branches are intact (arrowheads). (C) After coronary stenting of the middle RCA, the right ventricular branches of the RCA were jailed. (D) The ECG after stenting shows newly developed marked ST elevation in leads V1-V5, and slight ST elevation in the inferior leads (more in lead III than lead II).

Copyright © 2026 The Korean Association of Internal Medicine
This is an Open Access article distributed under the terms of the Creative Commons Attribution Non-Commercial License (http://creativecommons.org/licenses/by-nc/4.0/) which permits unrestricted noncommercial use, distribution, and reproduction in any medium, provided the original work is properly cited.

pISSN 1226-3303
eISSN 2005-6648
http://www.kjim.org

A 79-year-old male with hypertension was admitted with chest pain. An electrocardiogram (ECG) was obtained (Fig. 1A). The troponin I level was increased to 0.11 ng/mL (reference range, 0–0.04 ng/mL). Coronary angiography revealed an irregular stenosis of 80% in the middle portion of the right coronary artery (RCA) (Fig. 1B). The left coronary system exhibited no significant lesions. Balloon angioplasty and coronary stenting were performed over the middle RCA. After coronary stenting, the right ventricular (RV) branches were jailed (Fig. 1C), and he complained of recurrent chest pain.

A repeat ECG (Fig. 1D) showed newly developed marked ST elevation (STE) in leads V1-V5, and slight STE in the inferior leads (more in lead III than lead II). A repeat left coronary angiogram revealed no occlusion. Attempted revascularization of the RV branches failed, but his chest pain somewhat improved after an intracoronary infusion of nicorandil. The post-procedural echocardiogram revealed RV systolic dysfunction with a wall motion abnormality of the RV free wall, which was compatible with an RV myocardial infarction (MI, RVMI). The post-procedural troponin I level maximally increased to 7.7 ng/mL. His symptom and STE gradually improved, and he was discharged 4 days later.

Isolated STE due to RVMI is uncommon in clinical practice. Since RVMI usually occurs with left ventricular inferior infarction, the electrical current of injury from the left ventricle dominates the RV electrical forces. The typical ECG changes in this setting are STE in the inferior leads with concomitant ST depression in the precordial leads [1]. However, the ECG presentation of an isolated RVMI can mimic an anterior STEMI because of the anterior location of the RV. The absence of Q-wave development in the anterior precordial leads may help the diagnosis of RVMI [2], as was observed in current case.

REFERENCES

1. Geft IL, Shah PK, Rodriguez L, et al. ST elevations in leads V1 to V5 may be caused by right coronary artery occlusion and acute right ventricular infarction. Am J Cardiol 1984;53:991-996.
2. Hilliard AA, Nkomo VT, Mathew V, Prasad A. Isolated right ventricular infarction--an uncommon cause of acute anterior ST segment elevation. Int J Cardiol 2009;132:e51-e53.

Received : April 28, 2026
Accepted : May 11, 2026

Correspondence to
Melvin M. Scheinman, M.D., FHRS
Division of Cardiology, Section of Electrophysiology, University of California, 500 Parnassus Avenue, MUE-434, Box 1354, San Francisco, CA 94117, USA
Tel: +1-415-353-2554, Fax: +1-415-476-6260
E-mail: Melvin.Scheinman@ucsf.edu
https://orcid.org/0000-0001-6295-3753

CRedit authorship contributions
Chan-Hee Lee: conceptualization, data curation, writing - original draft; Young-Sang Jeong: investigation, data curation, writing - original draft, visualization; Melvin M. Scheinman: writing - review & editing, supervision

Conflicts of interest
The authors disclose no conflicts.

Funding
None