

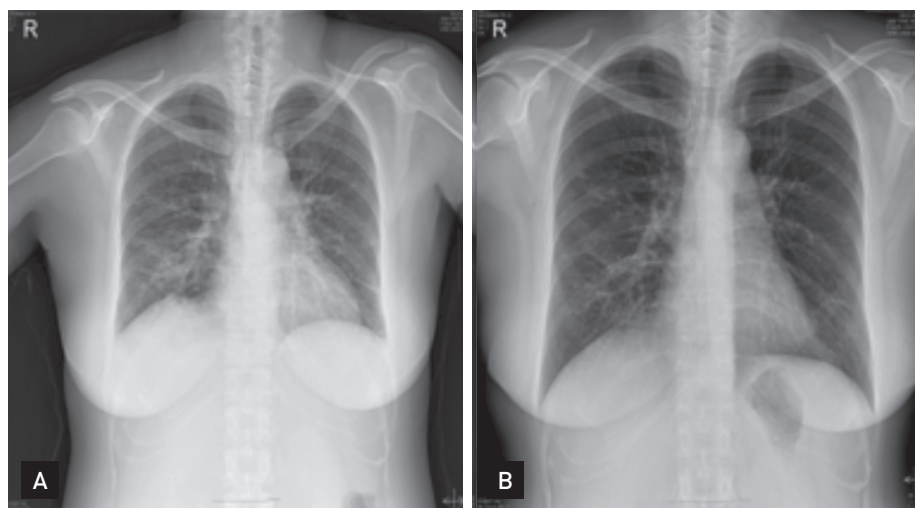
A case of Wegener's granulomatosis mimicking recurrent hemophagocytic lymphohistiocytosis

Sung Min Jung, Yun Hwa Jung, Hyun Jin Noh, In Sook Woo, and Chi Wha Han

Division of Hematology-
Oncology, Department of Internal
Medicine, The Catholic University
of Korea College of Medicine,
Seoul, Korea

Korean J Intern Med. 2014;29:393-397.
<http://dx.doi.org/10.3904/kjim.2014.29.3.393>

In the article cited above, Fig. 3 was input incorrectly. The correct figure is as following:



We apologize for any inconvenience that is may have caused.